

REVIEW ARTICLE OPEN



Clinical assessment, investigation, diagnosis and initial management of cerebral visual impairment: a consensus practice guide

Rachel Fiona Pilling^{1,2}✉, Louise Allen³, Richard Bowman⁴, John Ravenscroft⁵, Kathryn J Saunders⁶ and Cathy Williams⁷

© The Author(s) 2022

Cerebral Visual Impairment (CVI) is a common condition in the UK. Patients with conditions associated with CVI are frequently seen in paediatric ophthalmology clinics offering eye care professionals an opportunity to identify children proactively. In most cases CVI occurs as part of a neurodevelopmental condition or as a feature of multiple and complex disabilities. However, CVI can also be seen in children with apparently typical development. In some cases, high contrast visual acuity is normal and in other cases severely impaired. As such, identification of CVI requires evaluation of aspects of visual performance beyond high contrast acuity and consideration that visual function of those with CVI may fluctuate. Few paediatric ophthalmologists have received formal training in CVI. The detection and diagnosis of CVI varies across the UK and patients report hugely different experiences. A diagnosis of CVI is made based on professional clinical judgement and it is recognised that individual perspectives and local practice in the specific methodologies of assessment will vary. A systematic review and survey of professionals is underway to attempt to reach agreement on diagnostic criteria. Nonetheless, established pathways and published protocols can offer guidance on how a paediatric ophthalmology service can approach assessment of the child with suspected CVI. The purpose of this paper is to present a summary of research and clinical practice methods for detecting and diagnosing CVI in a paediatric ophthalmology outpatient setting. It represents current understanding of the topic and acknowledges the evolving nature of both practice and the evidence-base. A rapid literature review was undertaken to identify articles relating to clinical investigation of children with CVI. A focus group of QTVI and subject matter experts from sight loss charities was undertaken to address areas which were not covered by the literature review.

Eye; <https://doi.org/10.1038/s41433-022-02261-6>

INTRODUCTION

Cerebral Visual Impairment (CVI) is a common condition in the UK. Patients with conditions associated with CVI are frequently seen in paediatric ophthalmology clinics offering opportunity eye health professionals an opportunity to identify children proactively. In most cases CVI occurs as part of a neurodevelopmental condition or as a feature of multiple and complex disabilities. However, CVI can also be seen in children with apparently typical development. In some cases, high contrast visual acuity is normal and in other cases severely impaired. As such, identification of CVI requires evaluation of aspects of visual performance beyond high contrast acuity and consideration that visual function of patients with CVI may fluctuate. CVI has not historically been included in Royal College of Ophthalmologists trainee curriculum and as such trainees lack awareness of the condition. Few paediatric ophthalmologists have received formal training in CVI [1]. For these reasons, the detection and diagnosis of CVI varies across the UK and patients report hugely different experiences.

The purpose of this paper is to present a summary of research and clinical practice methods for detecting and diagnosing CVI in a paediatric ophthalmology outpatient setting (Box 1). It represents current understanding of the topic and acknowledges the evolving nature of both. A concise summary of this document has been reviewed by members of the UK CVI specialist interest group (eye health professionals from the UK).

What is cerebral visual impairment?

Cerebral visual Impairment (CVI) is an umbrella term which encompasses a wide range of brain-related visual problems [2]. Cerebral Visual Impairment is the commonest cause of visual impairment in children in the developed nations [3–6]. Whilst there is broad consensus around the features of CVI and the concept of visual difficulties not explainable by ocular findings [7], there are as yet no agreed diagnostic criteria or thresholds for diagnosis.

Some authorities regard impairments of visual acuity or visual field (not due to ocular or optic nerve pathology) as necessary for a diagnosis of CVI, while others regard any brain-based visual

¹University of Bradford, Bradford, England. ²Department of Ophthalmology, Bradford Teaching Hospitals, Bradford, UK. ³University of Liverpool, Liverpool, England. ⁴Great Ormond Street Hospital, London, England. ⁵University of Edinburgh, Edinburgh, UK. ⁶Ulster University, Coleraine, UK. ⁷University of Bristol, Bristol, England.
✉email: r.f.pilling@bradford.ac.uk

Received: 4 May 2022 Revised: 1 August 2022 Accepted: 12 September 2022
Published online: 18 October 2022

Box 1: Summary of questions arising from multidisciplinary consultation

What history, examination and investigations should be undertaken for a child attending an NHS paediatric ophthalmology clinic when referred with suspicion of cerebral visual impairment?
 What findings would constitute a diagnosis of cerebral visual impairment?
 What should be written in a report to the healthcare and education team?
 What support/advice/signposting/onward referral should be offered by a general paediatric ophthalmology team?

deficit as potentially part of CVI [8]. For the purposes of this document, we take the more inclusive final option, while awaiting agreement on national and international guidelines.

There is often no cure for the features of cerebral visual impairment: rather the impact of visual dysfunction is ameliorated by adopting strategies and modifications to the child's environment tailored to the child's unique combination of difficulties [9–11].

Current consensus for definition of CVI [7]

A verifiable visual dysfunction which cannot be attributed to disorders of the anterior visual pathways or any potentially co-occurring ocular impairment.

A diagnosis of CVI is made based on professional clinical judgement and it is recognised that individual perspectives and local practice in the specific methodologies of assessment will vary [8]. A multidisciplinary working group in Europe has been created to carry out a systematic review and survey professionals to reach agreement on diagnostic criteria. Nonetheless, established pathways and published protocols can offer guidance on how a paediatric ophthalmology service can approach assessment of the child with suspected CVI.

Epidemiology

Cerebral Visual Impairment is the most common cause of registrable visual impairment in the UK [12]. CVI has been reported as affecting 20–90% children with common neurodevelopmental conditions (prematurity, cerebral palsy, hypoxic ischaemic encephalopathy, hydrocephalus, meningitis, Down's syndrome [3–6, 13]) and children with special educational needs are 28 times more likely to encounter vision problems than typically developed children [14]. The CVI Project (www.thecviproject.co.uk) found that at least 3% of children in mainstream school—equating to one child in every classroom—had CVI-related visual difficulties [15]. This places CVI and related vision problems on a par with amblyopia as a common childhood vision disorder [16].

Broadly speaking, children with cerebral visual impairment have been reported as having one of three profiles:

- i. Those with marked/moderate developmental delay and impaired visual acuity as well other variable visual deficits.
- ii. Those with mild or no developmental delay, normal or near normal visual acuity and impaired oculomotor and vision processing abilities.
- iii. Those with mixed characteristics [17].
- There is emerging a fourth group.
- iv. Those who have functioned well and appeared asymptomatic until the point of decompensation.

Regardless of which group the child lies in or profile they present with, each will have significant visual difficulties affecting daily life, education and independence.

What is the role of the ophthalmologist in the identification and diagnosis of cerebral visual impairment?

Ophthalmologists play an important role in both exploring the visual development concerns of parents, teachers and other

health professionals and making a timely formal diagnosis to enable children to access services and/or support.

Figure 1 outlines the assessment and initial management of a child referred with suspected CVI. It is acknowledged that existing services may have alternative approaches. Collaborative working between paediatric, ophthalmology, developmental support services and education will refine local arrangements (Fig. 2).

Whilst it is beyond the scope of this document to specify a model of care a general paediatric ophthalmology department can be expected to support the diagnosis of CVI by:

- Excluding and/or managing co-existing ocular conditions (e.g. optic disc anomalies, structural anomalies such as cataract, coloboma), refractive error and accommodation dysfunction.
- Establishing by history-taking risk factors for, and symptoms of, CVI to enable proactive detection of visual dysfunction or behaviours indicative of such.
- Considering involvement of the whole healthcare team in particular paediatric and developmental disability teams, in establishing associated conditions.

How is cerebral-visual impairment diagnosed?

There are three main elements to the diagnosis of CVI (see Tables 1, 2). Where there is a positive finding in all three areas, it is probable that CVI is present. Where there is a positive finding in two of the three elements, CVI should be considered, and further evidence to support or exclude a diagnosis sought from parents or other professionals.

Children with CVI may have significant visual difficulties affecting daily life, education, and independence. The spectrum of dysfunction and presentations requires a curious, proactive, and flexible approach to history taking, examination and diagnosis which will differ for each child.

Diagnosis: history taking. History taking is an essential first step. The past medical history may elicit events related to birth injury, hydrocephalus, cerebral palsy, prematurity, meningitis and neurodevelopmental abnormalities (structural or metabolic). The use of inventories/questionnaires/structure history taking in eliciting descriptions of visual behaviours can be useful to direct a testing or clinical examination strategy and are considered in Section 6.

Diagnosis: documenting areas of visual difficulty. The broad features of CVI relate to visual acuity, viewing behaviour (fixation), supranuclear eye movements (pursuits or saccades) or field impairment. If any one of these is present in a child with other developmental delay, the child will need support to use their vision to access education. It is helpful for the family to have formal recognition and documentation of visual dysfunction, whether or not the individual ophthalmologist determines this to have met the threshold for a diagnosis of CVI. Raising suspicions of CVI at as early a stage in development as possible enables the child to access support and develop strategies or environmental adaptations to use their vision effectively. There should not be a delay in diagnosis while waiting for the child's development to allow for formal testing of acuity, visual fields or visuo-perceptual status (Visual inattention encompasses a wide variety of atypical visual behaviours, including visual avoidance, eccentric fixation, poor fixation, light gazing and visual stasis (being unable to look away from an object)).

Diagnosis: formal and informal testing. Deficits in higher visual functions can be elicited from a history or by informal or formal testing. Visuocognitive/visuoperceptual assessments are more commonly performed by occupational therapists, psychologists and other allied professionals. Basic (low cognitive demand) tests of visuoperceptual/visuocognitive skills are emerging. These tests

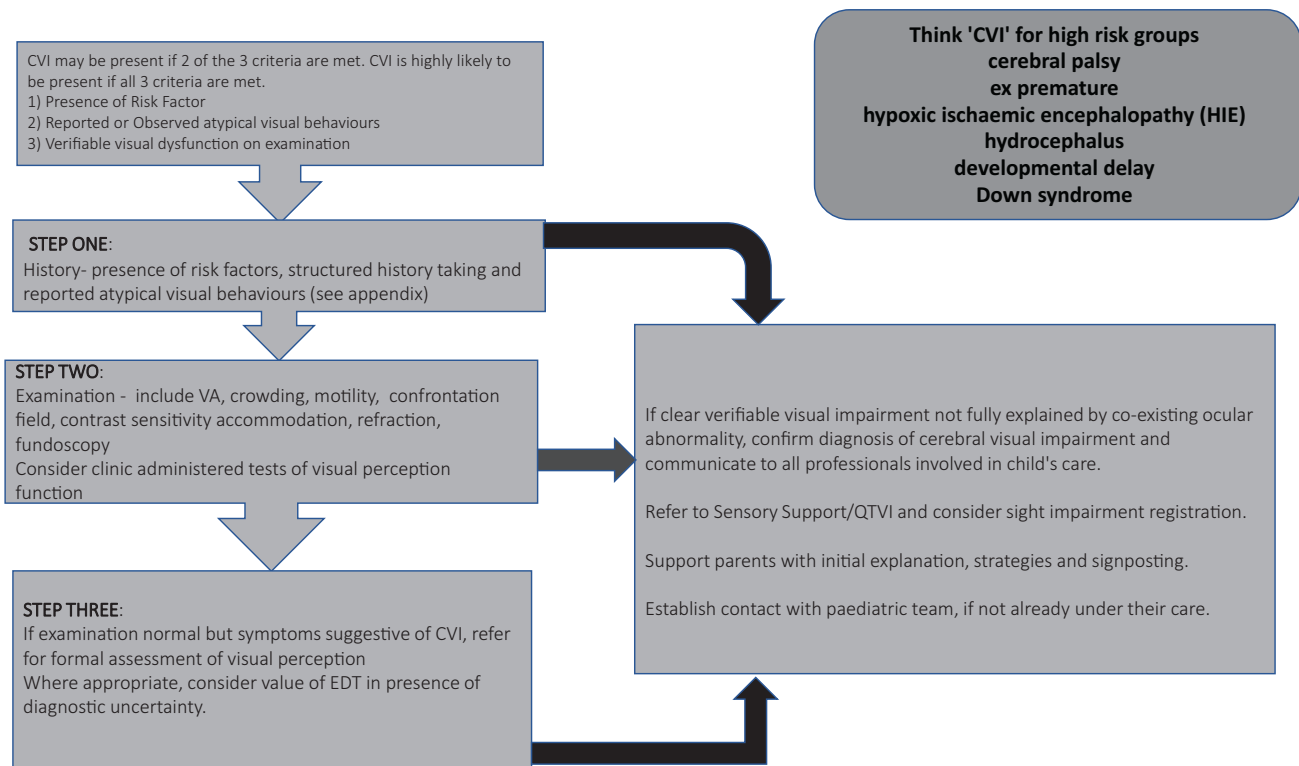


Fig. 1 Stepwise approach to the diagnosis of paediatric cerebral-visual impairment.

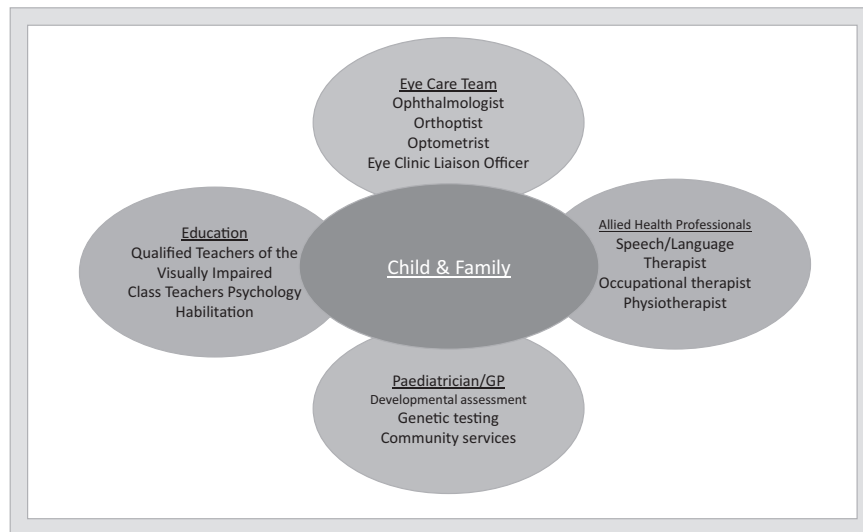


Fig. 2 The team around the child: agencies to involve with any child diagnosed with CVI. Multi-agency involvement in a child with suspected or confirmed Cerebral Visual Impairment.

can be performed by eye departments and/or teachers of the visually impaired and normative data are available [18] (see Appendix 1). Ophthalmologists with experience of these tools may choose to use them to confirm a diagnosis of CVI and highlight the specific visuoperceptual domains within which a child demonstrates impairment and therefore requires further assessment by relevant professionals as well as relevant support.

Examination and visual assessment

The overriding principle to hold central is that not every child needs every test. A testing strategy should be flexible and

inclusive. The skill lies in adapting testing techniques to the child's developmental ability rather than delaying a diagnosis until the child can engage with specific tests. This is similar to other areas of paediatric ophthalmology where the aim is to establish the most important things first and be prepared to repeat assessments if needed for confirmation.

The visual assessment required to make or exclude a diagnosis of CVI is in many cases within the remit of a general ophthalmology service using existing tools and equipment. Appendix 1 identifies the validated tests and tools which might be utilised.

Table 1. Cerebral-visual impairment diagnostic elements.

1. Developmental anomaly/positive risk factor for CVI	e.g. ex premature, cerebral palsy, Down's syndrome, hypoxic ischaemic encephalopathy, hydrocephalus, developmental delay.
2. Externally observed or reported symptoms of CVI and/or atypical visual function	e.g. Unexplained failure to progress at school; difficulty finding objects; difficulty with complexity; clumsiness; difficulty recognising people, shapes, places; difficulty with moving objects; eccentric visual behaviours; may include information from inventories/questionnaires.
3. CVI-related visual dysfunction elicited on examination in any combination of areas below (Table 2).	e.g. Traditional acuity tests, crowding test, contrast sensitivity or low contrast acuity; confrontation field, dynamic retinoscopy, refraction, oculomotor function (including pursuits, saccades), simple clinic-based perceptual tests.

Table 2. Commonly encountered cerebral-visual impairment related visual dysfunctions.

Lower visual function impairment	Higher visual function impairment ventral stream	Higher visual function impairment dorsal stream
Reduced binocular visual acuity (in particular with crowded testing) not due to refractive error at distance or near	Visual memory/recognition (impaired ability to name shapes, objects, letters, recognise faces, or facial gesture)	Impaired ability to notice more than one object at a time (simultanagnosia)
Abnormal fixation	Route finding/orientation (impaired ability to 'map' their world or a room in order to orient effectively through it)	Movement perception (impaired ability to see moving objects OR impaired ability to see objects unless they are moving)
Visual field deficit/inattention		Visual guided movement (impaired ability to reach for/locate objects/navigate steps/kerbs)
Oculomotor impairment (in particular jerky smooth pursuit, inaccurate saccades)		

The role of inventories/questionnaires in the diagnosis and management of CVI. Structured questions relating to the child's visual function can be helpful in eliciting signs and symptoms of CVI and may supplement general history taking. The child themselves will perceive their vision as 'normal' to them and is often unable to describe what is 'unusual' about their vision [19].

Whilst not essential for diagnosis, structured inventories/questionnaires can be useful in devising an examination strategy for the individual child.

Many inventories and questionnaires have been published as validated instruments [20–31], however no single tool has been shown to be reliable in the diagnosis of CVI [8]. Studies have shown that stand-alone questionnaires lack the sensitivity required for reliable diagnosis and their use as broad screening tools is likely to over-diagnose [32, 33]. Any particular behaviour, such as failing to find someone in a crowd, may have a variety of visual or non-visual causes. However, inventories/questionnaires are a useful prompt for parent and practitioner discussions and a way of identifying key problem areas in day-to-day life. A table of validated tools is provided in Appendix 2.

The 'Insight' inventory has been shown to be an effective tool in estimating visual-perceptual difficulties without formal testing [21]. When linked to targeted strategies to support the child in using their vision effectively, its use can facilitate improvement in function vision and quality of life [20, 21].

The role of investigations in the diagnosis of cerebral visual impairment

CVI is a clinical diagnosis made based on history taking, visual dysfunction (on examination or in the presence of behaviour suggestive of visual dysfunction) and the presence of an underlying risk factor. Therefore, formal investigations are often not required in the diagnosis of CVI. However, they can be useful when there is diagnostic uncertainty or to identify co-existing ocular/neurological pathology, particularly optic neuropathy which may be secondary to lesions in the primary visual pathway.

Neuroimaging. Most children presenting with developmental abnormalities have already had neuroimaging and reviewing a

previous scan can be useful. However, around a third of patients with CVI have no visible abnormality on routine structural imaging [5, 19]. The risk from general anaesthesia should be balanced against any potential benefit to the patient from undergoing neuroimaging. The evidence correlating visual dysfunction and CVI with MRI findings is weak [34] and imaging should not be seen as a primary investigation unless it is going to directly alter the management of the patient [35].

Electrodiagnostic Testing (EDT). Electrodiagnostic tests are not essential for the diagnosis of CVI [35]. They may have a role in the identification of retinal or optic nerve dysfunction where co-existing ophthalmic (e.g. nystagmus, high refractive error) and/or medical diagnoses (e.g. metabolic or genetic conditions) have a known association with retinal dystrophy. In the presence of normal acuity VEPs are unlikely to demonstrate any abnormalities [36].

Ocular Coherence Tomography (OCT). OCT of the optic disc is emerging as a tool within the diagnosis of CVI, particularly for children who cannot perform standard perimetry [37]. Periventricular leucomalacia (PVL) related disc cupping is a common finding [38–40]. Focal thinning of the ganglion cell layer has been found to be present in areas corresponding to visual field defects and sector asymmetry has been shown to be predictive of a visual field defect [41]. In the absence of sector asymmetry, visual field is likely to be normal or globally constricted [37].

Formal perimetry. Formal visual field assessment is not essential in the diagnosis of CVI; indeed, for many children it will be beyond their developmental abilities to perform such test. Perimetry may be useful in higher functioning children to demonstrate field loss and support sight impairment registration.

Visuo-perceptual or Psychometric testing. Visuo-perceptual testing is important in profiling of children with CVI to fully uncover the breadth of visual dysfunction a child may be experiencing [5, 9, 19, 42–46]. Visuo-perceptual tests often require good central visual acuity and well developed communication, motor and

cognitive ability in order for results to be meaningful. For children with cerebral-visual impairment in the context of marked developmental delay, the current tests are not accessible.

Psychometric tests do not form part of the core visual assessment; however it is important that ophthalmologists arrange or suggest referral to professionals (eg Neurodevelopmental Paediatricians, psychologists, occupational therapists or QTVIs) in the local area who have appropriate expertise. Some children with normal acuity and field will require such testing in order to demonstrate verifiable visual dysfunction to fulfil the diagnostic criteria and receive a confirmed diagnosis of CVI. It is also an ophthalmologist's role to liaise with multidisciplinary teams to establish a holistic picture of the child's wider neurological, physical and sensory status when exploring a diagnosis of CVI.

For those children who can participate, specialist ophthalmology/MDT clinics may wish to consider incorporating tests shown in table in Appendix 2.

Management of Children with CVI

Parents commonly cite a lack of support, signposting and information at diagnosis as a key barrier to them accessing services to support their children [11, 47]. Whilst each individual child will need a bespoke support package, simple adaptations to educational materials (such as enlarged font and/or fewer items per page) and environments (such as reducing clutter and/or considering area of best visual attention) help a lot of children [48]. Appendix 3 offers signposting to strategies which health, education and parents may find useful.

Ophthalmologists are well placed to offer initial explanations, advice, and referral on to other health, education, and social care professionals. It is essential that key ocular issues which may not be apparent to other professionals supporting the child, such as refractive errors, hypoaccommodation, impaired saccades and pursuits and field loss, are identified, managed and communicated effectively.

Whilst it is beyond the scope of this document to specify a model of care, where CVI is identified or suspected, ophthalmologists and their teams might undertake the following steps:

- i. Acknowledge the presence of CVI and provide an explanation of the nature of the child's visual disability, including signposting information.
- ii. Manage refractive error including bifocals for children with poor accommodative function.
- iii. Offer information on initial strategies based on clinical findings (e.g. field of attention, difficulties tracking objects, difficulty with clutter).
- iv. Contribute to effective report writing encompassing a description of the child's visual function, beyond a simple acuity measurement and share this report with parents and the wider team supporting the child.
- v. Arrange referral to education service (sensory support team, QTVI, habilitation services).
- vi. Consider sight impairment registration, (or notification to VINCYP if in Scotland) regardless of visual acuity, if the child is judged to be significantly disadvantaged by their visual function.
- vii. Refer to the Eye Clinic Liaison Officer (where available) and signpost charity/support organisations (Appendix 4).
- viii. Where appropriate, to arrange onward referral for further assessment and support (e.g. sensory services, occupational therapy, psychology, low vision clinic).

Prognosis. It is important to explain to parents that while there is no 'cure' for CVI, it is not true to say that 'nothing can be done'. Improvements in function can be seen over time in some

cases, and support from education, habilitation, occupational therapy, and family can be transformative as children learn strategies to maximise the efficiency of their vision, finding ways to 'make it easier to see' [48]. It should be acknowledged that as children mature, the visual burden or expectations on them increase. This often brings an apparent drop in function which can be managed by exploring and adopting new strategies for emerging situations and needs.

Effective report writing in CVI

It is important that eye health professionals provide accessible and meaningful information about the child's visual strengths and weaknesses to education teams to facilitate provision of support [6, 11, 14, 22, 43, 47, 49, 50]. Inclusion of any visual impairment within a child's Education Health and Care Plan (EHCP) or equivalent is crucial but often overlooked.

The following key phrases have been suggested by teachers of the visually impaired (QTVI) as being helpful to sensory service providers.

- i. Brief explanations of what CVI is (e.g. *The child's brain has difficulty processing the information it receives from the eyes in order to make sense of the world around them*).
- ii. Inclusion of the diagnostic term 'Cerebral Visual Impairment' where the ophthalmologist is confident this is warranted.
- iii. A statement indicating the need for support to access education. *'This child's visual dysfunction will impact on their ability to access education/develop social skills/mobilise safely and independently including road safety/communicate effectively'*.
- iv. Recommendation that visual impairment be included in the child's EHCP or equivalent.

Elements of the visual assessment important to include in a report are shown below.

- Visual acuity, or object size and distance at which it is seen
- Size and contrast of print the child can easily access
- Areas of visual field inattention e.g. inferior loss, or hemianopia or global constriction
- Ocular motility—smooth pursuits and saccades—ability to track objects, locate new objects
- Duration of/Fluctuation in visual attention
- Any abnormal head posture adopted to maximise vision e.g. looks to side of motility problems etc
- Contrast sensitivity
- Requirement for glasses and when they should be used
- Information from observation or history regarding visual clutter, visual memory, shape, place, face recognition
- Results from questionnaires/inventories which highlight strategies which match the child's areas of visual strength/weakness.

REFERENCES

1. Pilling RF. Are we blind to the causes of visual impairment in children? A baseline survey of eye health professionals' awareness of cerebral visual impairment. *Ophthalmic Physiol Opt.* 2022;42:237.
2. Dutton GN. Cerebral visual impairment in children: the importance of classification. *Dev Med Child Neurol.* 2021;63:245. <https://doi.org/10.1111/dmcn.14684>.
3. Dutton GN, Saeed A, Fahad B, Fraser R, McDaid G, McDade J, et al. Association of binocular lower visual field impairment, impaired simultaneous perception, disordered visually guided motion and inaccurate saccades in children with cerebral visual dysfunction—a retrospective observational study. *Eye.* 2004;18:27–34. <https://doi.org/10.1038/sj.eye.6700541>.
4. Ho ML, Mansukhani SA, Brodsky MC. Prenatal or perinatal injury? Diagnosing the cortically blind infant. *Am J Ophthalmol.* 2020;211:56–62. <https://doi.org/10.1016/j.ajoph.2019.10.026>.

5. Chokron S, Kovarski K, Zalla T, Dutton GN. The inter-relationships between cerebral visual impairment, autism and intellectual disability. *Neurosci Biobehav Rev*. 2020;114:201–10. <https://doi.org/10.1016/j.neubiorev.2020.04.008>.
6. Black SA, McConnell EL, McKerr L, McClelland JF, Little JA, Dillenburger K, et al. In-school eyecare in special education settings has measurable benefits for children's vision and behaviour. *PLoS ONE*. 2019;14:e0220480. <https://doi.org/10.1371/journal.pone.0220480>.
7. Sakki HEA, Dale NJ, Sargent J, Perez-Roche T, Bowman R. Is there consensus in defining childhood cerebral visual impairment? A systematic review of terminology and definitions. *Br J Ophthalmol*. 2018;102:424–32. <https://doi.org/10.1136/bjophthalmol-2017-310694>.
8. Ortibus E, Fazzi E, Dale N. Cerebral visual impairment and clinical assessment: the European perspective. *Semin Pediatr Neurol*. 2019;31:15–24. <https://doi.org/10.1016/j.spen.2019.05.004>.
9. McConnell EL, Saunders RJ, Little JA. What assessments are currently used to investigate and diagnose cerebral visual impairment (CVI) in children? A systematic review. *Ophthalmic Physiol Opt*. 2021;41:224–44. <https://doi.org/10.1111/opo.12776>.
10. Hall Lueck A, Dutton GN. Vision and the brain. New York: American Printing House for the Blind; 2015.
11. Goodenough T, Pease A, Williams C. Bridging the gap: parent and child perspectives of living with cerebral visual impairments. *Front Hum Neurosci*. 2021;15:689683. <https://doi.org/10.3389/fnhum.2021.689683>.
12. Teoh LJ, Solebo AL, Rahi JS, on behalf of the British Childhood Visual Impairment and Blindness Study Iterest Group. Visual impairment, severe visual impairment, and blindness in children in Britain (BCVIS2): a national observational study. *Lancet Child Adolesc Health*. 2021. [https://doi.org/10.1016/S2352-4642\(20\)30366-7](https://doi.org/10.1016/S2352-4642(20)30366-7).
13. Woodhouse JM. Investigating and managing the child with special needs. *Ophthalmic Physiol Opt*. 1998;18:147–52.
14. Donaldson LA, Karas M, O'Brien D, Woodhouse JM. Findings from an opt-in eye examination service in English special schools. Is vision screening effective for this population? *PLoS ONE*. 2019;14:e0212733. <https://doi.org/10.1371/journal.pone.0212733>.
15. Williams C, Pease A, Warnes P, Harrison S, Pilon F, Hyvärinen L, et al. Cerebral visual impairment-related vision problems in primary school children: a cross-sectional survey. *Dev Med Child Neurol*. 2021. <https://doi.org/10.1111/dmcn.14819>.
16. Tailor V, Bossi M, Greenwood JA, Dahmann-Noor A. Childhood amblyopia: current management and new trends. *Br Med Bull*. 2016;119:75–86. <https://doi.org/10.1093/bmb/ldw030>.
17. Sakki H, Bowman R, Sargent J, Kukadia R, Dale N. Visual function subtyping in children with early-onset cerebral visual impairment. *Dev Med Child Neurol*. 2020. <https://doi.org/10.1111/dmcn.14710>.
18. Williams C, Gilchrist ID, Fraser S, McCarthy HM, Parker J, Warnes P, et al. Normative data for three tests of visuocognitive function in primary school children: cross-sectional study. *Br J Ophthalmol*. 2015;99:752–6. <https://doi.org/10.1136/bjophthalmol-2014-305868>.
19. Lueck AH, Dutton GN, Chokron S. Profiling children with cerebral visual impairment using multiple methods of assessment to aid in differential diagnosis. *Semin Pediatr Neurol*. 2019;31:5–14. <https://doi.org/10.1016/j.spen.2019.05.003>.
20. Hellgren K, Jacobson L, Frumentio P, Bolk J, Ådén U, Libertus ME, et al. Cerebral visual impairment captured with a structured history inventory in extremely preterm born children aged 6.5 years. *J Aapos*. 2020;24:28.e1–8. <https://doi.org/10.1016/j.jaapos.2019.11.011>.
21. Tsirka A, Liasis A, Kuczynski A, Vargha-Khadem F, Kukadia R, Dutton G, et al. Clinical use of the Insight Inventory in cerebral visual impairment and the effectiveness of tailored habilitational strategies. *Dev Med Child Neurol*. 2020;62:1324–30. <https://doi.org/10.1111/dmcn.14650>.
22. Duke R, Eyang K, Burton K, MacLeod D, Dutton GN, Gilbert C, et al. The effect of visual support strategies on the quality of life of children with cerebral palsy and cerebral visual impairment/perceptual visual dysfunction in Nigeria: study protocol for a randomized controlled trial. *Trials*. 2019;20:417. <https://doi.org/10.1186/s13063-019-3527-9>.
23. Macintyre-Beon C, Young D, Calvert J, Ibrahim H, Dutton GN, Bowman R. Reliability of a question inventory for structured history taking in children with cerebral visual impairment. *Eye*. 2012;26:1393. <https://doi.org/10.1038/eye.2012.154>.
24. Philip SS, Tsheringlinga S, Thomas MM, Dutton GN, Bowman R. A validation of an examination protocol for cerebral visual impairment among children in a clinical population in India. *J Clin Diagn Res*. 2016;10:NC01–4. <https://doi.org/10.7860/JCDR/2016/22222.8943>.
25. Dutton GN. Structured history taking to characterize visual dysfunction and plan optimal habilitation for children with cerebral visual impairment. *Dev Med Child Neurol*. 2011;53:390. <https://doi.org/10.1111/j.1469-8749.2010.03900.x>.
26. Rossi A, Gnesi M, Montomoli C, Chirico G, Malerba L, Merabet LB, et al. Neonatal Assessment Visual European Grid (NAVEG): unveiling neurological risk. *Infant Behav Dev*. 2017;49:21–30. <https://doi.org/10.1016/j.infbeh.2017.06.002>.
27. Fazzi E, Micheletti S. Questionnaires as screening tools for children with cerebral visual impairment. *Dev Med Child Neurol*. 2020;62:891. <https://doi.org/10.1111/dmcn.14497>.
28. Ortibus E, Laenen A, Verhoeven J, De Cock P, Casteels I, Schoolmeesters B, et al. Screening for cerebral visual impairment: value of a CVI questionnaire. *Neuropediatrics*. 2011;42:138–47. <https://doi.org/10.1055/s-0031-1285908>.
29. Ben Itzhak N, Vancleef K, Franki I, Laenen A, Wagemans J, Ortibus E. Visuo-perceptual profiles of children using the Flemish cerebral visual impairment questionnaire. *Dev Med Child Neurol*. 2020;62:969–76. <https://doi.org/10.1111/dmcn.14448>.
30. Lee J, Kim MG, Park HY, Nam KE, Park JH. Visual assessment of preterm and full-term infants under the age of 12 months using the Preverbal Visual Assessment questionnaire. *Early Hum Dev*. 2021;153:105289. <https://doi.org/10.1016/j.earlhumdev.2020.105289>.
31. Chang MY, Borchert MS. Methods of visual assessment in children with cortical visual impairment. *Curr Opin Neurol*. 2021;34:89–96. <https://doi.org/10.1097/wco.0000000000000877>.
32. Gorrie F, Goodall K, Rush R, Ravenscroft J. Towards population screening for cerebral visual impairment: validity of the five questions and the CVI questionnaire. *PLoS ONE*. 2019;14:e0214290. <https://doi.org/10.1371/journal.pone.0214290>.
33. van Genderen M, Dekker M, Pilon F, Bals I. Diagnosing cerebral visual impairment in children with good visual acuity. *Strabismus*. 2012;20:78–83. <https://doi.org/10.3109/09273972.2012.680232>.
34. Philip SS, Guzzetta A, Chorna O, Gole G, Boyd RN. Relationship between brain structure and Cerebral Visual Impairment in children with Cerebral Palsy: a systematic review. *Res Dev Disabil*. 2020;99:103580. <https://doi.org/10.1016/j.ridd.2020.103580>.
35. Handa S, Saffari SE, Borchert M. Factors associated with lack of vision improvement in children with cortical visual impairment. *J Neuroophthalmol*. 2018;38:429–33. <https://doi.org/10.1097/WNO.0000000000000610>.
36. Handley SE, Thompson DA, Prise KL, Liasis A. ERGs on the brain: the benefits of simultaneous flash retinal and cortical responses in paediatric cerebral visual impairment. *Doc Ophthalmol*. 2018;136:223–7. <https://doi.org/10.1007/s10633-018-9631-4>.
37. Jacobson L, Lennartsson FMN. Retinal ganglion cell topography predicts visual field function in spastic cerebral palsy. *DMCN*. 2020;62:1100–6. <https://doi.org/10.1111/dmcn.14545>.
38. Groth SL, Donahue SP, Reddy A, Sarma A, Wushensky C. Periventricular leukomalacia in patients with pseudo-glaucomatous cupping. *Am J Ophthalmol*. 2020;211:31–41. <https://doi.org/10.1016/j.ajo.2019.10.016>.
39. Jacobson L, Hård AL, Svensson E, Flodmark O, Hellström A. Optic disc morphology may reveal timing of insult in children with periventricular leukomalacia and/or periventricular haemorrhage. *Br J Ophthalmol*. 2003;87:1345–9. <https://doi.org/10.1136/bjo.87.11.1345>.
40. Jacobson L, Hellström A, Flodmark O. Large cups in normal-sized optic discs: a variant of optic nerve hypoplasia in children with periventricular leukomalacia. *Arch Ophthalmol*. 1997;115:1263–9. <https://doi.org/10.1001/archophth.115.10.1263>.
41. Jacobson L, Lennartsson F, Nilsson M. Ganglion cell topography indicates pre- or postnatal damage to the retro-geniculate visual system, predicts visual field function and may identify cerebral visual impairment in children—a multiple case study. *Neuroophthalmology*. 2019;43:363–70. <https://doi.org/10.1080/01658107.2019.1583760>.
42. Vancleef K, Janssens E, Petr   Y, Wagemans J, Ortibus E. Assessment tool for visual perception deficits in cerebral visual impairment: reliability and validity. *Dev Med Child Neurol*. 2020;62:118–24. <https://doi.org/10.1111/dmcn.14304>.
43. Hyv  rinen L, Walthe R, Freitag C, Petz V. Profile of visual functioning as a bridge between education and medicine in the assessment of impaired vision. *Strabismus*. 2012;20:63–8. <https://doi.org/10.3109/09273972.2012.680235>.
44. Williams C, Northstone K, Sabates R, Feinstein I, Emond A, Dutton GN. Visual perceptual difficulties and under-achievement at school in a large community-based sample of children. *PLoS ONE*. 2011;6:e14772. <https://doi.org/10.1371/journal.pone.0014772>.
45. Duke RE, Nwachukwu J, Torty C, Okorie U, Kim MJ, Burton K, et al. Visual impairment and perceptual visual disorders in children with cerebral palsy in Nigeria. *Br J Ophthalmol*. 2020. <https://doi.org/10.1136/bjophthalmol-2020-317768>.
46. Williams C, Pease A, Warnes P, Harrison S, Pilon F, Hyv  rinen L, et al. Cerebral visual impairment-related vision problems in primary school children; a cross-sectional study. *Dev Med Child Neurol*. 2021. <https://doi.org/10.1111/dmnc.14819>.
47. McConnell EL, Black SA, McClelland JF, McKerr L, Dillenburger K, Anketell P, et al. Parents and teachers of children in special education settings value in-school eyecare and written reports of visual status. *PLoS ONE*. 2020;15:e0238779. <https://doi.org/10.1371/journal.pone.0238779>.

48. Pilling RF. Make it easier: 3-word strategies to help children with cerebral visual impairment use their vision more effectively. *Eye*. 2022. <https://doi.org/10.1038/s41433-021-01920-4>.
49. Williams C, Northstone K, Borwick C, Gainsborough M, Roe J, Howard S, et al. How to help children with neurodevelopmental and visual problems: a scoping review. *Br J Ophthalmol*. 2014;98:6–12. <https://doi.org/10.1136/bjophthalmol-2013-304225>.
50. Pilling RF, Outhwaite L. Are all children with visual impairment known to the eye clinic. *Br J Ophthalmol*. 2017;101:472–4. <https://doi.org/10.1136/bjophthalmol-2016-308534>.
51. Pilling RF, Outhwaite L, Bruce A. Assessing visual function in children with complex disabilities: the Bradford visual function box. *Br J Ophthalmol*. 2016;100:1118–21. <https://doi.org/10.1136/bjophthalmol-2015-307558>.
52. Bowman R, McCulloch DL, Law E, Mostyn K, Dutton GN. The mirror test for estimating visual acuity in infants. *Br J Ophthalmol*. 2009;94:882–85.
53. Dekker MJ, Pilon F, Bijveld MM, de Wit GC, van Genderen MM. Crowding ratio in young normally sighted children. *Strabismus*. 2012;20:49–54. <https://doi.org/10.3109/09273972.2012.680233>.
54. Elgohary AA, Abuelela MH, Eldin AA. Age norms for grating acuity and contrast sensitivity measured by Lea tests in the first three years of life. *Int J Ophthalmol*. 2017;10:1150–3. <https://doi.org/10.18240/ijo.2017.07.20>.
55. Little J-A, McCullough S, McClelland J, Jackson AJ, Saunders KJ. Low contrast acuity measurement: does it add value in the visual assessment of Down syndrome and cerebral palsy populations? *Investig Ophthalmol Vis Sci*. 2013;54:251–7.
56. LEA Vision Test Limited. Lea Mailbox Game. (available from <https://leatestest.com/vision-test-system>).
57. Vancleef K, Janssens E, Petré Y, Wagemans J, Ortibus E. Assessment tool for visual perception deficits in cerebral visual impairment: development and normative data of typically developing children. *Dev Med Child Neurol*. 2020;62:111–7. <https://doi.org/10.1111/dmcn.14303>.
58. Pilling RF, Little SM. Evaluation of the role of the colour tent in vision stimulation for children with complex disabilities and cerebral visual impairment: a feasibility study. *Br J Vis Impairment*. 2019;38:104–14.

ACKNOWLEDGEMENTS

We wish to acknowledge the contributions of the CVI SIG for their comments in the consultation for this document, and the members of the CVI Education Focus Group for their contributions.

AUTHOR CONTRIBUTIONS

RFP devised the project, main conceptual idea, focus groups and literature review. RFP produced the initial paper. LA, RB, JR, KJS, and CW provided analysis, critical feedback and contributed to writing of the paper.

COMPETING INTERESTS

RFP is co-creator of the Bradford Visual Function Box.

ADDITIONAL INFORMATION

Correspondence and requests for materials should be addressed to Rachel Fiona Pilling.

Reprints and permission information is available at <http://www.nature.com/reprints>

Publisher's note Springer Nature remains neutral with regard to jurisdictional claims in published maps and institutional affiliations.

APPENDIX 1: VISUAL ASSESSMENT TOOLS FOR CHILDREN WITH AND WITHOUT VERBAL/MOTOR SKILLS

Visual function	Test for verbal/motor children	Test for pre-verbal/pre-motor children
Visual acuity: Near and Distance	logMAR letter tests (e.g. Keeler crowded letter test, Sonksen logMAR letters) LogMAR picture	Cardiff acuity test Teller/Keeler grating acuity test Questions 1–11 of PreViAs [30]

Visual function	Test for verbal/motor children	Test for pre-verbal/pre-motor children
	tests (e.g. Kay picture test, Lea symbols)	
Visual attention: Duration distance and object size	By observation	Bradford Visual Function Box [6, 51] Mirror test [26, 52] Puppet Face Neonatal Assessment Visual European Grid [26]
Crowding ratio [33, 53] for Near and Distance (difference between acuity for single optotypes vs. crowded optotypes with both eyes open).	logMAR letter tests (e.g. Keeler crowded letter test, Sonksen logMAR letters) LogMAR picture tests (e.g. Kay picture test, Lea symbols)	N/A
Contrast Sensitivity or Low Contrast Acuity	Low contrast letter/picture charts (Lea symbols, ETDRS)	Hiding Heidi [54] Cardiff Contrast test [55]
Confrontation visual fields, including inferior visual field	Using appropriate object size and mindful of visual field inattention: horizontal and vertical	Using appropriate object size and mindful of visual field inattention: horizontal and vertical
Simultanagnosia	Ability to detect a 'new' object in a different area of visual field	
Pupil reactions		
Pursuit and saccades	Using appropriate object size and mindful of visual field inattention; horizontal and vertical	
Accommodation	Dynamic retinoscopy	
Object orientation	Lea mailbox [56] (for children over developmental age 4 years)	
Ability to match shapes visually	Lea rectangles [18, 56] (for children over developmental age 6 years)	Lea 3D puzzle test
Oculo-motor coordination (Reach and Grab)	Using a suitable size object based on visual acuity. Observing accuracy, speed and eye/head alignment during task.	
Ability to detect moving objects	CVIT 3–6 [42, 57]	By observation

Visuo-perceptual tests

Tool	Notes/ref (e.g. age range, area of function assessed)
Child Visual Impairment Test for 3–6 year olds (CVIT 3–6) [42]	12-min (tablet/online interaction visual tasks)
Beery Visual-Motor Integration test (VMI)	3 tasks
L94 visual perception battery	8 tasks
Test of Visual Perceptual Skills—Revised (TVPS-R)	7 subscales
Developmental Test of Visual Perception (DTVP)	5 subscales

APPENDIX 2: CEREBRAL-VISUAL IMPAIRMENT INVENTORIES/ QUESTIONNAIRES

Tool	Notes/reference
Insight/Visual Skills Inventory	[21, 23] http://www.ctevh.org/Conf2017/Workshops/407/407%20-%20Insight.html 52 item questionnaire with links to strategies
PreVias	[30] Tool for children under 12 months
TeACH	https://www.teachvi.net/ 3 questionnaires for children of differing age (6+, under 6) or motor abilities (version for non-ambulant children). [28]
Flemish CVI questionnaire	[29] https://cdn-links.lww.com/permalink/coop/a/coop_2012_05_31_lehman_656_sdc1.pdf 46 item tool designed to draw out behaviours associated with CVI

APPENDIX 3: STRATEGIES TO SUPPORT CHILDREN WITH CVI

Insight: Approaches for Visual Perceptual Difficulties [22] <http://www.ctevh.org/Conf2017/Workshops/407/407%20-%20Insight.html>.

Make It Easier To See [48] <https://makeiteasiertosee.co.uk/>.

Ulster University CVI Strategies

<https://www.ulster.ac.uk/research/topic/biomedical-sciences/research/optometry-and-vision-science/vision-resources/professionals/cerebral-visual-impairment-assessment>.

Colour Tents [58] https://cvisociety.org.uk/news.php?cat_id=250.

APPENDIX 4: UK CVI CHARITIES AND PATIENT SUPPORT ORGANISATIONS

www.cvisociety.org.

www.cviscotland.org.



Open Access This article is licensed under a Creative Commons Attribution 4.0 International License, which permits use, sharing, adaptation, distribution and reproduction in any medium or format, as long as you give appropriate credit to the original author(s) and the source, provide a link to the Creative Commons license, and indicate if changes were made. The images or other third party material in this article are included in the article's Creative Commons license, unless indicated otherwise in a credit line to the material. If material is not included in the article's Creative Commons license and your intended use is not permitted by statutory regulation or exceeds the permitted use, you will need to obtain permission directly from the copyright holder. To view a copy of this license, visit <http://creativecommons.org/licenses/by/4.0/>.

© The Author(s) 2022